

Autonomic Dysreflexia

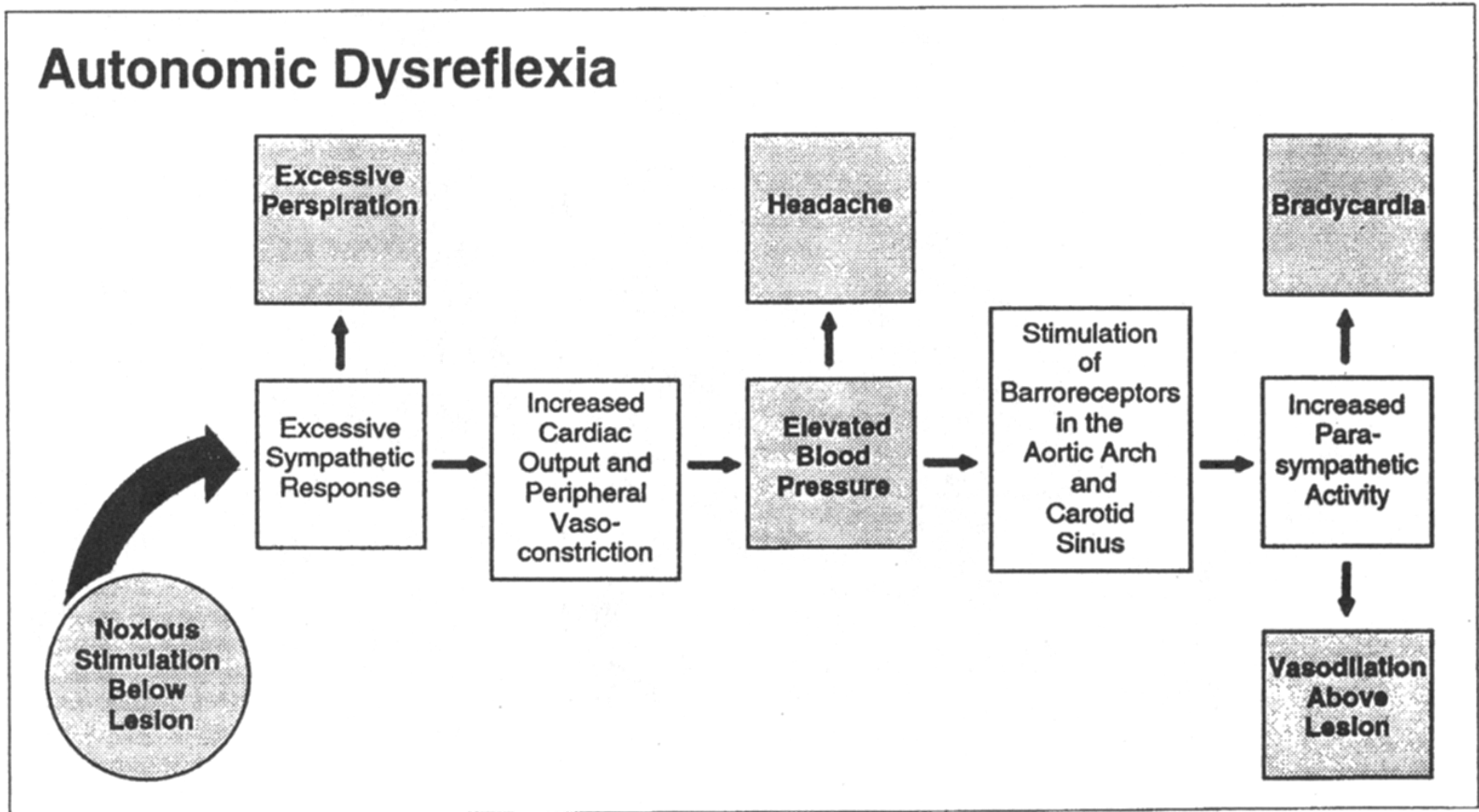


Figure 24-5. Schematic Representation of Autonomic Dysreflexia. Clinical signs and symptoms are in the darkened boxes. (From Somers, MF: Spinal Cord Injury. Functional Rehabilitation. Appleton & Lange, Norwalk, CT, 1991, p 31, with permission.)